

<http://heanoti.com/index.php/hn>



SYSTEMATIC REVIEW ARTICLE

URL of this article: <http://heanoti.com/index.php/hn/article/view/hn30203>

Management of Diabetic Foot Ulcers on Adjunctive Therapy: A Systematic Review

Zulfikar Peluw^{1(CA)}, La Rakhmat Wabula²

^{1(CA)}Doctoral Program in Health Medicine, Faculty of Medicine, Diponegoro University, Indonesia;
zulfikr.peluw@gmail.com (Corresponding Author)

²Departement of Nursing, STIKes Maluku Husada, Indonesia; la.rakhmat.wabula-2017@fkip.unair.ac.id

ABSTRACT

Diabetic foot ulcers is a common complication of Diabetes Mellitus and was became world health global issue. The adjunctive therapy has become the latest modality in recent years, but there were not much significant research to support its utilization as a diabetic foot ulcer treatment standard. This review aims to assess the effectiveness of various adjunctive therapies for diabetic foot ulcers. Using electronic databases, such as Scopus, PubMed, Embase, Ovid Technologies, Cumulative Index to Nursing and Allied Health Literature (CINAHL), Cochrane, and Web of Science databases were systematically searched in June 2013 for systematic reviews published after 2004 and randomized controlled trials (RCTs) published in 2012–2013. Many therapeutic modalities are available to treat DFU. Quality high-level evidence exists for standard care such as off-loading. Evidence for adjunctive therapies such as negative pressure wound therapy, skin substitutes, and platelet-derived growth factor can help guide adjunctive care but limitations exist in terms of evidence quality. Given the diversity of therapies, future studies must define the populations that most benefit from each therapy by utilizing clear and strict inclusion and exclusion criteria.

Keywords: Adjunctive therapy, Diabetic foot ulcers

INTRODUCTION

Background

The worldwide epidemic of type 2 diabetes mellitus has brought increased attention to some of its common complications, such as foot ulcers, secondary infections, and limb amputations. The development of diabetic ulcers is driven primarily by the effect of peripheral sensory neuropathy on foot biomechanics (foot deformity). Lower extremity ulcers are responsible for 20% of diabetic-related hospital admissions and are a major source of morbidity and loss of income for diabetes mellitus. Treatment is often prolonged and is sometimes unsuccessful, and the patients are prone to serious complications⁽¹⁾.

In Indonesia, diabetes mellitus (DM) afflicts 9.9% of the population over 40 years of age, of which 30% suffer from lower extremity disease. Development of diabetic foot ulcer (DFU) is associated with staggeringly high mortality rates of 16.7% at 12 months and 50% at 5 years—rates comparable to mortality rates of colon cancer⁽²⁾. Furthermore, patients with dm and new-onset dfu have significantly reduced survival rates compared with age- and ex-matched controls with dm but without dfus (72 and 86% 3-year survival, respectively)⁽³⁾. In the Indonesia, healthcare cost are estimated to be 5.4 times higher in the first year after a diagnosis of DFU than for patients with dm without an ulcer^(2,3). Therefore, management and intervention of patients with DM and DFU must be adequately addressed before onset of severe complications. Unfortunately, dm is associated with a 15-25% lifetime risk for developing DFU, and once ulceration occurs, healing is difficult and lower extremity amputations (leas) common⁽²⁾.

Fortunately, there are going efforts towards international consensus on management and rapid communication on enhancing standard of care and reviewing novel therapies. These therapies address various mechanism of dfu formation in order to achieve wound healing. DFU standart of care is critical; however, for those not responding to standard care, new adjunctive modalities may provide opportunities for healing. Yet, while treatment options have expanded in recent years, the cost effectiveness and efficacy of these modalities remain in question.

Purpose

This review intends to identify recent evidence-based evaluations of all dfu therapies, focusing exclusively on high-level evidence. Furthermore, it identifies gaps in current data and suggests direction for further investigation.

METHODS

Using electronic databases, such as Scopus, PubMed, Embase, Ovid Technologies, Cumulative Index to Nursing and Allied Health Literature (CINAHL), Cochrane, and Web of Science databases were systematically searched in June 2013 for systematic reviews published after 2004 and randomized controlled trials (RCTs) published in 2012–2013. Databases were searched using the keywords diabetic foot, wound healing, diabetes complications, skin ulcer, and diabetes mellitus. Searches were filtered to retrieve systematic reviews, meta-analyses, and RCTs published in English.

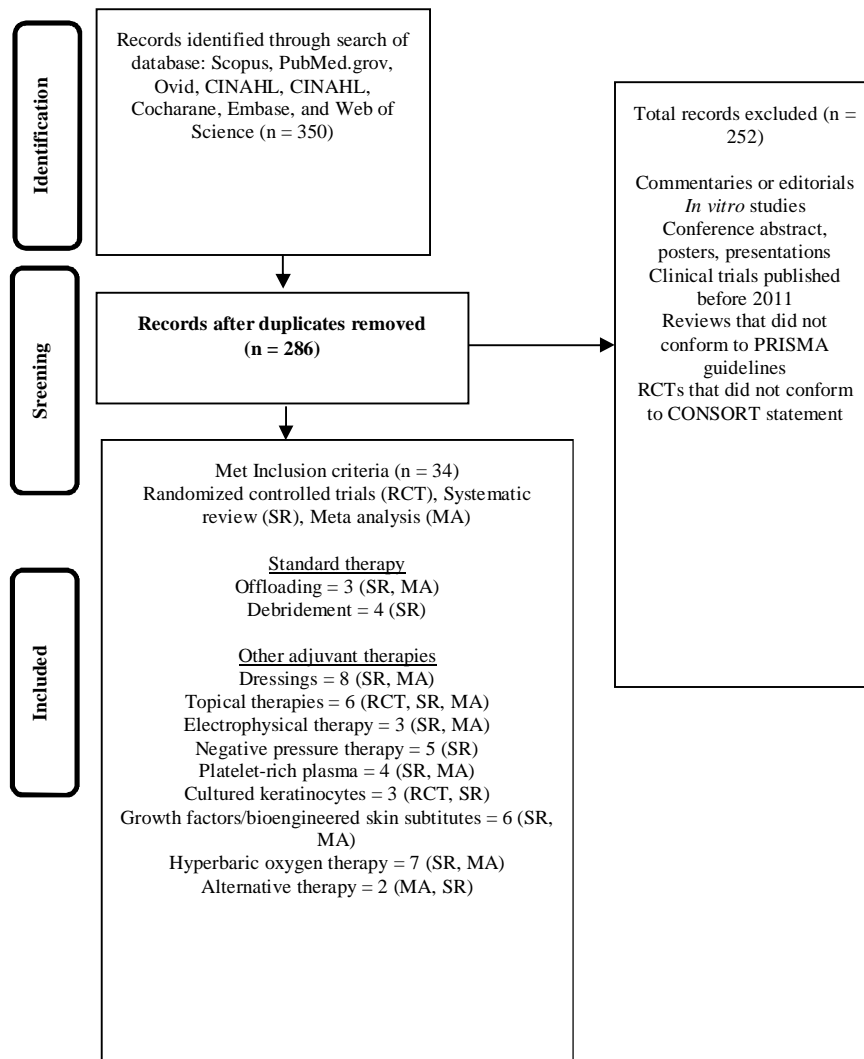


Figure 1. Flow chart depicting study selection process. *CONSORT* Consolidated Standards of Reporting Trials, *MA* meta-analysis, *PRISMA* (Preferred Reporting Items for Systematic Reviews and Meta-Analyses, *RCT* randomized controlled trial, *SR* systematic review

RESULTS

Overall, 34 studies met inclusion and exclusion criteria (Fig. 1). The modalities covered in these trials include negative pressure wound therapy (NPWT) (n = 5), growth factors (n = 3), bioengineered skin substitutes (BSS) (n = 6), cultured keratinocytes (n = 3), hyperbaric oxygen therapy (HBOT) (n = 7), off-loading (n = 3), debridement (n = 4), alternative therapies (n = 2), dressings (n = 8), topical therapies (n = 6), platelet-rich plasma (PRP) (n = 4), and electrophysical therapy (n = 3). These studies are summarized in Table 1. To enhance the discussion, we first discuss currently accepted standard of care and then present the evidence supporting it. Evidence on adjuvant therapies not currently considered part of routine standard care is discussed. Finally, a summary of the quality of evidence is presented (Table 1).

DISCUSSION

Current Standardized Approach to Diabetic Foot Ulcers (DFUs)

Current standard of care for DFUs includes assessment for vascular disease, skin, soft tissue or bone infection, and neuropathy⁽⁴⁾. The former two should be addressed, if present, with optimization of vascular supply and antibiotics. For neuropathic foot ulcers, redistributing pressure (off-loading) is critical (see evidence discussed in Sect. 3.2). A variety of approaches to off-loading exist, including bed rest, wheelchairs, crutches, foot inserts, therapeutic shoes, casts, or by surgical procedures⁽⁵⁾.

Although the total contact cast (TCC) is considered the 'gold standard' off-loading device by many because it is associated with the highest healing rates, it has limited use because it requires trained staff for application and removal, may cause trauma if improperly applied, and is contraindicated in infection, contralateral foot ulcer, significant arterial insufficiency, and balance problems⁽⁵⁾. Indeed, a recent study found that fewer than 2% of diabetic foot specialists utilize TCC⁽²⁾. Therefore the 'instant contact cast' made by applying fiberglass or CobanTM (3M, Minneapolis, MN, USA) around a removable cast walker has been increasingly used and may be equally effective⁽⁶⁾. Successful off-loading is frequently affected by poor patient compliance, given that these devices limit performance of daily activities. Therefore, the best device is the one that best adapts to the patient and allows a continuous use. Some surgical procedures have been reported to achieve offloading, including Achilles tendon lengthening, silicone injections, metatarsal head resection, and arthroplasties⁽⁷⁾.

Debridement is also considered part of DFU standard care (see evidence discussed in Sect. 3.2). It allows removal of callus and abnormal edge tissue, necrotic tissue, and reduction of bacterial biofilms and excess matrix metalloproteinases (MMPs)^(4,8). Debridement may be surgical, enzymatic (collagenase), autolytic (i.e., occlusive), mechanical (wet-to-dry dressing, lavage), or biologic (larval). Of these debridement types, surgical debridement is preferred for DFU. Surgical debridement is presumed to encourage healing by stimulating growth factor production and by converting a chronic non-healing wound environment into a more responsive 'acute healing' environment⁽⁵⁾. The optimal frequency for DFU debridement is not clear but often is performed either weekly or as needed based on the formation of non-viable tissue^(9,10).

Assessment commonly includes weekly wound measurements and if healing is not observed (such as 50 % wound size reduction over 4 weeks), adjunctive therapies are often considered. Evidence exists for cellular constructs (ApligrafTM, Organogenesis, Canton, MA and DermagraftTM, Shire, La Jolla, CA, USA), selected cadaveric acellular constructs (GraftJacketTM, KCI, San Antonio, TX, USA), and recombinant platelet-derived growth factor (RegrenexTM, Smith and Nephew, Fort Worth, TX, USA) for superficial wounds. Hyperbaric oxygen and negative pressure wound therapy are used for deeper or complicated wounds⁽¹¹⁾.

Evidence Supporting Standard of Care Above

Off-Loading

Three systematic reviews evaluated off-loading techniques for the treatment of DFUs. All report that non-removable devices are more effective than removable devices⁽¹²⁻¹⁴⁾. Given this finding, it is not recommended that therapeutic footwear be used to treat DFUs⁽¹⁵⁾. Compared with removable devices, the superiority of non-removable devices may be due to improved compliance⁽¹⁶⁾ and/or decreased physical activity of subjects⁽¹⁷⁾, rather than superior plantar pressure reduction. Only one review evaluated surgical off-loading procedures. Lewis and Lipp⁽⁷⁾ reported that Achilles tendon lengthening with TCC was more effective than TCC alone at 7-month and 2-year follow-up (relative risk [RR] at 7 months 3.41, 95 % confidence interval [CI] 1.42-8.18; RR at 2 years 2.23, 95 % CI 1.32-3.76). However, this procedure is expensive, and long-term benefits are not well studied. The authors note that post-surgical scarring or worsening of diabetic motor

neuropathy, for example, might decrease the benefits of Achilles tendon lengthening. For these reasons, it is recommended to pursue surgical methods only if alternative methods are unsuccessful.

Table 1. Summary of quality of evidence for the treatment of diabetic foot ulcer*

| Therapeutic intervention | Quality of evidence |
|---------------------------------|-----------------------|
| Off-loading | Moderate quality |
| Debridement | Moderate quality |
| Dressings | Insufficient evidence |
| Topical therapies | Moderate quality |
| Electrophysical therapy | Moderate quality |
| Negative pressure wound therapy | Moderate quality |
| Platelet-rich plasma | Moderate quality |
| Cultured keratinocytes | Moderate quality |
| Growth factors | Moderate quality |
| Bioengineered skin substitutes | Moderate quality |
| Hyperbaric oxygen therapy | Moderate quality |
| Alternative therapy | Insufficient evidence |

* The quality of evidence was judged by the American College of Physicians (ACP) criteria ⁽¹⁸⁾

Debridement

Four systematic reviews concluded that good-quality evidence for a beneficial effect of debridement on ulcer healing is lacking ⁽¹⁹⁾. Surgical debridement was evaluated in two reviews; neither found statistically significant improvements in healing with surgical debridement ⁽²⁰⁾. Of note, subjects undergoing surgery generally received several days of antibiotics and were told to off-load the affected area for several weeks after surgery. Both of these factors may contribute to beneficial effects and neither is controlled for in available clinical studies. Despite this, a statistically significant benefit of surgical debridement was not found. More recently, a large retrospective review of 312,744 wounds from 525 centers supported routine frequent debridement ⁽²¹⁾.

A Cochrane review evaluated the evidence for different types of debridement, including autolytic debridement, enzymatic debridement, and larval therapy, and found that autolytic debridement with hydrogels was superior to standard wound care, based on differences in healing rates (RR 1.84, 95 % CI 1.3–2.61) ⁽¹⁹⁾. However, evaluated studies were small and of low quality, and the authors note that the benefits of hydrogels may not be limited to debridement, as this therapy also increases moisture in the wound bed ⁽¹⁹⁾. Evidence is lacking for larvae therapy; a recent review noted that it did not significantly improve healing time or amputation risk in participants with DFUs ⁽²¹⁾. No complete sets of data were found that evaluate enzymatic therapy for DFUs.

Evidence Supporting Adjuvant Therapies Not Currently Considered Standard of Care

Dressings

The primary goal of dressings in patients with DFU is to create a moist occlusive wound environment that prevents infection and further trauma as well as absorbs chronic wound fluid.

Multiple Cochrane reviews evaluated the efficacy of advanced dressings, such as hydrogels, foams, alginates, and hydrocolloids in DFU management ⁽²²⁾. Hydrogels improve healing in superficial DFUs compared with basic dressings; however, comparisons with other advanced dressings are lacking ⁽²³⁾. Studies of other dressing types, including silver, hydrofiber, and collagen dressings, found no statistically significant difference in wound healing compared with basic dressings and were limited by lack of high-quality data, lack of continuity in measured outcomes, and small sample size ⁽²⁴⁾, but have found benefit for periwound skin.

Summary: Based on our review, the data suggest that advanced dressings may achieve better reduction in contact dermatitis and periwound maceration, common complications of wound dressings, rather than improving time to wound closure. One RCT, which did not meet inclusion criteria, found no difference in wound resolution for three different dressings, despite large cost disparities ⁽²³⁾. Ultimately, there is insufficient evidence to support which type of dressing best maintains a moist, occlusive wound healing environment.

Topical Therapies

Topical therapies include a range of therapeutic cutaneous applications aimed at improving wound healing by various mechanisms. An RCT failed to demonstrate a significant difference in overall healing and amputation rates after application of topical honey. However, honey therapy significantly increased healing rate compared with povidone iodine dressings ($p < 0.0001$)⁽²⁵⁾. A systematic review by Shaw et al.⁽²⁶⁾ evaluated topical phenytoin but only 2 of the 14 studies were specific for DFU, and only one of which demonstrated statistically significant reduction in wound size. A sponsored phase II RCT of NorLeu3-A, an angiotensin analog, showed promising results, with DFUs healing at a median of 8.5 weeks compared with 22 weeks in placebo ($p = 0.04$)⁽²⁷⁾. Lastly, a meta-analysis of hyaluronic acid (HA) evaluated four DFU-specific studies⁽²⁰⁾. Two RCTs analyzed HA scaffolding with keratinocytes versus standard of care in DFUs, with a primary outcome of complete healing at 12 weeks. Neither study demonstrated statistically significant improvement, though a trend towards healing was observed (RR 0.90; 95 % CI 0.76–1.04; p -value 0.25). Two additional studies evaluated HA matrix alone versus standard of care in neuropathic ulcers. Meta-analysis of these studies found improved healing rates at 12 weeks post-treatment (RR 0.24; 95 % CI 0.24–0.49; p -value < 0.0001) with fewer non-healed ulcers in the HA group⁽²⁸⁾. Systematic reviews looking at various methods of topical therapy were not able to find a comprehensive analysis comparing each method, nor were they able to determine one superior therapy⁽²⁹⁾.

Summary: There is moderate-quality evidence to support the use of various topical therapies; however, the strength of recommendation is low given study limitations and lack of comparative efficacy trials.

Electrophysical Therapy

Electrophysical therapy is an umbrella term for various treatments delivered by transmittal of energy from electrical, ultrasound, light/laser, and electromagnetic sources. Electrical stimulation wound therapy (ESWT) produces shortpulse electrical stimuli intended to mimic the body's natural electrical system and stimulate wound repair. Electrical stimulation may also improve perfusion, which can also contribute to improving healing. It may also stimulate the migration of various wound-modifying cells including keratinocytes, fibroblasts, macrophages, and neutrophils via various signaling mechanisms⁽³⁰⁾. Unfortunately, multiple different methods for electrical stimulation have been used clinically, with widely varying physiological rationales, making comparisons between studies difficult.

Nevertheless, a single meta-analysis evaluated various electrophysical modalities, including ESWT, phototherapy, and ultrasound in treatment of DFUs and found statistically significant evidence to support their use ($p = 0.002$)⁽²⁵⁾. Two additional systematic reviews evaluated electrical stimulation and shockwave therapy RCTs and determined the majority of the studies to be too methodologically weak or lacking in sample size to provide statistically significant results⁽³⁰⁾. Only one study was able to show an improved trend towards healing at 12 weeks with electrical stimulation⁽³⁰⁾.

Summary: These studies were conducted with moderate quality of evidence. Unfortunately, few conclusions could be drawn from these reports given the small sample size and poor methodological quality of the included studies. Kwan et al.⁽²⁵⁾ concluded that there was enough preliminary evidence to support larger randomized trials.

Negative Pressure Wound Therapy

Five systematic reviews compared NPWT with standard care or advanced moist wound therapy for DFUs and nonhealing post-amputation wounds in diabetic patients⁽³¹⁾. Game et al.⁽²⁷⁾ reported that two methodologically sound RCTs reported improved healing times and reduced risk of minor amputations with NPWT. An expert panel formulated recommendations based on the available literature and determined that NPWT should be considered in the following situations: (1) for post-operative Texas grade 2 and 3 diabetic foot wounds without ischemia, (2) to prevent amputation or re-amputation, and (3) to facilitate healing by secondary intention⁽¹⁷⁾.

Many of the reviewed trials were of poor to moderate quality, and the systems and methods of applying therapies used were heterogeneous. None of the studies examined change in bacterial colonization of the wounds, participant quality of life, or cost effectiveness.

Summary: Moderate-quality evidence suggests that NPWTs improve healing of DFUs and non-healing postamputation wounds compared with standard wound care. Many questions remain regarding ideal patient population and cost effectiveness.

Platelet-Rich Plasma, Cultured Keratinocytes, Growth Factors, and Skin Substitutes

Among other elements, wound healing requires a functional wound bed. Topical growth factors and BSS target the aberrant wound bed of a chronic ulcer to stimulate intrinsic epidermal and dermal elements necessary for healing of chronic wounds.

Platelet-Rich Plasma

A 2012 Cochrane review did not find statistically significant evidence to support the use of PRP in treating chronic wounds⁽³²⁾. Two of the RCTs included in the Cochrane study were DFU specific and did not find a statistically significant difference between PRP and control in DFU treatment (RR 1.16; 95 % CI 0.57–2.35). Overall, the study was unable to establish evidence-based support of PRP by ulcer etiology or by the procedure used to obtain autologous PRP.

A separate meta-analysis of five RCTs comparing DFU-specific healing found the use of PRP to be an effective adjunctive therapy in wound healing (95 % CI 2.94–20.31) only if used in combination with other therapies in a multidisciplinary approach⁽³³⁾. Of note, the study was unable to establish a reference value for PRP concentration consistent with each study and was therefore unable to recommend a therapeutic dose for DFU treatment⁽³⁴⁾. Lastly, two additional systematic reviews found six studies addressing the use of PRP in wounds but were unable to determine significant benefit given the limitations of the studies, which included sample size, poorly established endpoints, and elaborate exclusion criteria. One RCT did find improved healing at 12 weeks (intervention 79 % vs. control 46 %; $p < 0.05$); time to healing (intervention $7.0 \pm$ standard deviation [SD] 1.9 vs. 9.2 ± 2.2 weeks; $p < 0.05$); and percent area reduction (intervention 96.3 ± 7.8 vs. control 81.6 ± 19.7 ; $p < 0.05$). However, reviewers stated that the study's inclusion and exclusion criteria were unclear and were surprised by healing rates given the high incidence of bone exposure in pre-treatment wounds⁽³⁵⁾.

Allogeneic Keratinocytes

Living skin equivalents comprise live skin cells that release growth factors prompting new growth. In an RCT, allogeneic neonatal foreskin keratinocytes achieved complete wound closure in 100 % of DFUs versus 69 % of control patients ($p < 0.05$)⁽³⁴⁾. The experimental group also had shorter healing time (35 days) than the control group (57 days). However, this study was single-blind, and the etiology of each ulcer was not sufficiently ruled out for possible neuro-ischemia. The authors acknowledged the necessity for larger studies and the need for DFU standard of care, including debridement and infection control, as essential to healing outcomes⁽³⁶⁾. Two additional systematic reviews found two separate RCTs comparing allogeneic keratinocytes; however, both lack of complete data set and poor methodology prevented further analysis⁽³⁷⁾.

Growth Factors

Three systematic reviews evaluated the use of growth factors for DFUs⁽³⁸⁾. A systematic review of growth factors and BSS included nine RCTs of growth factors. Studied growth factors included becaplermin ($n = 6$), recombinant human epidermal growth factor (rhEGF, $n = 2$), and basic fibroblast growth factor (bFGF) ($n = 1$)⁽²¹⁾. All described studies had significant methodological limitations, including in some lack of blinding and failure to provide sample size calculations. Becaplermin, a recombinant platelet-derived growth factor, is the only US FDA-approved drug for treatment of DFUs and has been shown to significantly increase the proportion of healed ulcers and decrease healing time when used as adjuvant therapy with standard wound care ($p < 0.05$ in three RCTs and two meta-analyses). In a non-inferiority study, no statistically significant difference in effectiveness was seen between becaplermin and porcine small intestine submucosa, an advanced wound matrix implant ($p = 0.245$). Therapy with rhEGF (0.04 and 0.015 %) was significantly superior to standard wound care plus placebo in two trials. One study that compared bFGF with standard wound care failed to find a benefit of bFGF.

Bioengineered Skin Substitutes and Skin Grafting

Six reviews evaluated BSS for the treatment of DFUs⁽³⁹⁾. All found BSS superior to standard wound care; however, these conclusions were based on studies of limited quality. Two cellular constructs are commercially available in the USA: a dermal equivalent (DermagraftTM, Shire, La Jolla, CA, USA) and a bilayered construct (ApligrafTM, Organogenesis, Canton, MA, USA) and were found superior to standard wound care. Two reviews reported processed cadaveric acellular dermis (GraftJacketTM, KCI, San Antonio, TX, USA) superior to standard wound care⁽²⁹⁾. PromogranTM, a composite of collagen and oxidized regenerated cellulose (Systagenix, Gatwick, West Sussex, UK), ($n = 1$) and HyalograftTM, cultured autologous fibroblasts seeded onto

an HA-derived scaffold (Anika Therapeutics, Bedford, MA, USA), (n = 1) were not significantly superior to standard therapy⁽⁴⁰⁾. However, Teng et al.⁽³⁴⁾ suggest that the lack of significant effect in the study of Hyalograft™ may be due to an inadequate number of applications. In this study, Hyalograft™ was applied only one to two times, significantly fewer than in all other studies. No evidence of increased adverse events was reported in the reviewed studies.

Summary: Only limited conclusions can be drawn from these studies given that reviewed studies had multiple methodological limitations. Available data suggest that the addition of growth factors and metabolically active BSS Dermagraft®, Apligraf®, and GraftJacket® increases the likelihood of complete ulcer healing. This effect may be dose dependent.

Hyperbaric Oxygen Therapy

Adjunctive treatment with systemic HBOT is thought to accelerate wound healing by reducing tissue hypoxia⁽¹⁴⁾. Patients are placed in a compression chamber of 100 % oxygen at a pressure of at least 1.4 ATM. The oxygen dose and number of sessions are not standardized and vary between studies. Kranke et al.⁽⁴¹⁾, for example, evaluated eight trials: seven used chamber pressures ranging from 2.2 to 3.0 ATA and sessions lasted between 45–120 min. Most trials included between 20 and 40 sessions, while one trial used only four sessions over 2 weeks.

Two recent systematic reviews^(42,43) that included both prospective and retrospective studies concluded that adjunctive therapy with HBOT significantly increased the likelihood of ulcer healing (RR 2.33, 95 % CI 1.51–3.60)⁽¹³⁾ and significantly reduced the risk of major amputation (RR 0.29, 95 % CI 0.19–0.44), with benefits persisting at the 1- to 3-year follow-up (RR of healing 2.97, p<0.01.) Game et al.⁽²⁷⁾ note that high-quality evidence is limited, but a methodologically sound study found that subjects receiving HBOT were significantly more likely to heal within 12 months (p = 0.03). However, a 2012 Cochrane review limited to RCTs found that while HBOT increased healing of DFUs evaluated at 6 weeks (RR 5.20, 95 % CI 1.25–21.66; p = 0.02.), this benefit was no longer evident at 1-year follow-up⁽⁴⁴⁾. Furthermore, the Cochrane review did not find that HBOT decreased the risk of major amputations (RR 0.36, 95 % CI 0.11–1.18; p = 0.08).

Differences in data analysis and study selection among reviews likely explain these discrepancies. The Cochrane review was limited to RCTs, while the other two reviews also included non-randomized and retrospective studies, which increased the study's power at the expense of introducing bias into the analyses. Also, because individual trials were heterogeneous in patient populations, outcomes measures, and ulcer characteristics, the reviewers selectively chose to exclude some trials from their analysis. Liu et al.⁽¹⁴⁾ excluded one RCT from their analysis because it reported healing outcomes only with conservative measures, excluding those requiring surgery. This increases the likelihood of detecting a protective effect of HBOT on risk of amputation. Also, when Kranke et al.⁽⁴¹⁾ repeated their analysis without one trial of patients at high risk for amputation, their analysis did reveal a significant reduction of major amputation risk with HBOT therapy (p = 0.0009.) Due to the limited number of available studies, these small differences in analyses can significantly affect the results.

These discrepancies highlight the need for future, methodologically rigorous, appropriately powered, and methodologically standardized studies.

Summary: HBOT is frequently used, but because of a lack of a definitive efficacy study or well done effectiveness studies, this treatment remains, as Margolis and colleagues have pointed out in their recent analysis, controversial^(13,42). More research is necessary to define the patient population that would most benefit from this therapy. The finding that the benefits of HBOT may be limited to short-term follow-up should be further explored, as this may have significant implications regarding the cost effectiveness of this intervention.

Alternative Therapy

Only two systematic reviews were found that evaluated evidence for adjunctive oral Chinese herbal therapies⁽²⁴⁾. Meta-analysis of six studies studying different oral herbal preparations suggests that adding Chinese herbal medications to standard therapy improves the likelihood of complete ulcer healing (RR 0.62, 95 % CI 0.39–0.97)⁽¹⁵⁾. Side effects of therapy were mild, and adverse events were not significantly different between groups. Topical herbal preparations were not included in this analysis. Five of the six individual trials were judged to be of low quality, and only one was a randomized, double-blinded trial. Also, the herbal remedies were different across studies, making comparison and clinical recommendations difficult. The authors note that the most frequently used herbs were *Radix Angelicae sinensis*, *Flos Carthami Tinctorii*, *Semen Persicae*, and *Radix astragal*.

Another review noted that an oral Chinese herbal formulation did not improve healing of necrotic/gangrenous ulcers compared with placebo. The same review noted that ANGIPARS™ herbal

preparation (administered orally, topically, or intravenously) improved healing of DFUs, but supporting studies were methodologically flawed⁽¹⁶⁾.

Summary: Evidence is insufficient to make clinical recommendations regarding the safety or efficacy of oral Chinese oral supplements when used adjunctively with standard wound therapy.

CONCLUSION

Good-quality evidence is lacking for many of the described treatment modalities, and future studies are critical to better define the indications, therapeutic benefits, and adverse effects of each intervention. Given the diversity of therapies, future studies must define the populations that most benefit from each therapy by utilizing clear and strict inclusion and exclusion criteria. Also, baseline subject and ulcer characteristics should be described to allow comparison among trials and to define the indications of each modality. This is especially relevant to justify the use of new and expensive therapies that may be appropriate only for specific subsets of patients. Future study protocols should also incorporate a comprehensive set of outcome measures, including complete wound healing, wound healing rate, ulcer recurrence, pain, cost effectiveness, and quality of life. Most studies described in this review only evaluate healing rate or complete healing and disregard impact on quality of life and cost effectiveness. Given that compliance has been shown to be a critical factor in treatment success, parameters such as pain and quality of life should be evaluated. Of note, future studies should include subgroup analysis to evaluate treatment efficacy stratified by subject characteristics, including subject age, sex, smoking history, body mass index, and diabetes control. A recently published study protocol meets each of these criteri^a₍₃₅₎.

REFERENCES

1. Gregg EW, Gu Q, Williams D, Rekenire N De, Cheng YJ, Geiss L, et al. Prevalence of lower extremity diseases associated with normal glucose levels, impaired fasting glucose, and diabetes among U.S. adults aged 40 or older. *Diabetes Care*. 2007;77:485–8.
2. Lamont P, Franklyn K, Rayman G, Boulton AJM. Update on the Diabetic Foot 2012: The 14th Biennial Malvern Diabetic Foot Conference. *Diabetologia*. 2013;
3. Incidence, Outcomes, and Cost of Foot Ulcers in Patients with Diabetes. *Diabetes Care*. 1999;22(3).
4. Apelqvist J. Practical guidelines on the management and prevention of the diabetic foot Based upon the International Consensus on the Diabetic Foot (2007) Prepared by the International Working Group on the Diabetic Foot. 2008;24(January).
5. Boulton AJM, Armstrong DG, Albert SF, Frykberg RG, Hellman R, Kirkman MS, et al. Special Article COMPREHENSIVE FOOT EXAMINATION AND RISK ASSESSMENT*. *Diabetes Care*. 2008;14(5):576–83.
6. Assessment CE, Committee G. Academia and Clinic Annals of Internal Medicine The Development of Clinical Practice Guidelines and Guidance Statements of the American College of Physicians: Summary of. 2010;
7. Lewis J, Lipp A. Pressure-relieving interventions for treating diabetic foot ulcers (Review). *Diabetologia*. 2013;(1).
8. Alma BRMI, Anchez LUZPR. A Randomized Trial of Two Irremovable Off-Loading Devices in the Management of Plantar Neuropathic Diabetic Foot. *Diabetes Care*. 2005;28(3).
9. Chang HR, Aksenov IV. Spectrophotometry for Xanthochromia. *Diabetes Care*. 2004;1694–5.
10. Ethods M. D ia b e t ic F e e t P r e v e n t i o n. *Diabetes Care*. 2010;33(7):1460–3.
11. Morona JK, Buckley ES, Jones S, Reddin EA, Merlin TL. Comparison of the clinical effectiveness of different off-loading devices for the treatment of neuropathic foot ulcers in patients with diabetes: a systematic review and meta-analysis. *Diabetes Care*. 2013;(December 2012):183–93.
12. Reiber GE, Ledoux WR. Epidemiology of Diabetic Foot Ulcers and Amputations: Evidence for Prevention. *Diabetes Care*. 2002;
13. Bennett M, Kranke P. Systematic review of hyperbaric oxygen in the management of chronic wounds. *Diabetes Care*. 2005;24–32.
14. Liu R, Li L, Yang M, Boden G, Yang G. Systematic Review of the Effectiveness of Hyperbaric Oxygenation Therapy in the Management of Chronic Diabetic Foot Ulcers. *Mayo Clin Proc [Internet]*. 2013;88(2):166–75. Available from: <http://dx.doi.org/10.1016/j.mayocp.2012.10.021>
15. Study AC. Annals of Internal Medicine Risk Factors for Amputation in Patients with Diabetes. *Diabetes Care*. 2017;117(2):97–105.
16. Causal Pathways for Incident L o w e r - E x t r e m i t y Ulcers in Patients. *Diabetes Care*. 1999;22(1).
17. Therapies SR, Ulcers DF. Skin Replacement Therapies for Diabetic Foot Ulcers. *Diabetes Care*. 2008;31(4):2007–8.
18. Abbott CA, Carrington AL, Ashe H, Bath S, Every LC, Griffiths J, et al. The North-West Diabetes Foot Care Study: incidence of, and risk factors for, new diabetic foot ulceration in a community-based patient cohort. *Diabetes Care*. 2002;377–84.

19. Edwards J. Debridement of diabetic foot ulcers (Review). 2009;(4).
20. Lebrun E, Tomic-canic M, Kirsner RS. The role of surgical debridement in healing of diabetic foot ulcers. 2010;433–8.
21. Wilcox JR, Carter MJ, Covington S. Frequency of Debridements and Time to Heal A Retrospective Cohort Study of 312 744 Wounds. 2015;149(9):1050–8.
22. Jc D, Meara OS, Deshpande S, Speak K. Alginate dressings for healing diabetic foot ulcers (Review). 2012;(2).
23. Jc D, Meara OS, Deshpande S, Speak K. Hydrogel dressings for healing diabetic foot ulcers (Protocol). 2011;(5).
24. Jeffcoate WJ, Price PE, Phillips CJ, Game FL, Mudge E, Davies S, et al. Randomised controlled trial of the use of three dressing preparations in the management of chronic ulceration of the foot in diabetes. 2009;13(54).
25. Kwan RL, Cheing GL, Vong SK, Lo SK. Electrophysical therapy for managing diabetic foot ulcers : a systematic review. 2012;
26. Dumville JC, Soares MO, Meara SO, Cullum N. Systematic review and mixed treatment comparison : dressings to heal diabetic foot ulcers. 2012;1902–10.
27. Game FL, Löndahl M, Jeffcoate WJ. A systematic review of interventions to enhance the healing of chronic ulcers of the foot in diabetes. 2012;28(Suppl 1):119–41.
28. Voigt J, Driver VR. Hyaluronic acid derivatives and their healing effect on burns , epithelial surgical wounds , and chronic wounds : A systematic review and meta-analysis of randomized controlled trials. 2012;317–31.
29. Shaw J, Hughes CM, Lagan KM, Bell PM. Epidemiology And Health Services Research. The clinical effect of topical phenytoin on wound healing : a systematic review. 2007;997–1004.
30. Dpm T, Dpm PK, Dpm LAL, Thakral G, Lafontaine J, Najafi B, et al. Electrical stimulation to accelerate wound healing. 2017;(February).
31. Birke-sorensen H, Bruhin A, Chariker M, Depoorter M. Evidence-based recommendations for the use of negative pressure wound therapy in chronic wounds : Steps towards an international. 2011;(February 2010).
32. Villela DL, Lu V. Evidence on the use of platelet-rich plasma for diabetic ulcer : A systematic review. 2010;28(April):111–6.
33. Mj M, Aj M, Solà I, Ja E, Bolívar I, Rodríguez L, et al. Autologous platelet-rich plasma for treating chronic wounds (Review). 2012;(10).
34. Teng YJ, Li YP, Wang JW, Yang KH, Zhang YC, Wang YJ, et al. original article Bioengineered skin in diabetic foot ulcers. 2010;
35. Pecoraro RE, Ahroni JH, Boyko EJ, Stensel VL. Chronology and Determinants of Tissue Repair in Diabetic Lower-Extremity Ulcers. 1991;40(OCTOBER):1305–13.
36. Buchberger B, Follmann M, Freyer D, Huppertz H, Ehm A, Wasem J, et al. The Evidence for the Use of Growth Factors and Active Skin Substitutes for the Treatment of Non-Infected Diabetic Foot Ulcers (DFU): A Health Technology Assessment (HTA). 2011;472–9.
37. Noble-bell G, Forbes A. A systematic review of the effectiveness of negative pressure wound therapy in the management of diabetes foot ulcers. 2008;5(2):233–42.
38. Burgess EM. Pathways to Diabetic Basis for Prevention. 1990;13(5):513–21.
39. You H, Han S, Lee J, Chang H. Treatment of diabetic foot ulcers using cultured allogeneic keratinocytes — A pilot study. 2010;1–9.
40. Brownrigg JRW, Apelqvist J, Bakker K, Schaper NC, Hinchliffe RJ. Abstracts 1723. J Vasc Surg [Internet]. 2013;57(6):1723. Available from: <http://dx.doi.org/10.1016/j.jvs.2013.04.032>
41. Kranke P, Mh B, M MJ, Schnabel A, Se D, Weibel S. Hyperbaric oxygen therapy for chronic wounds (Review). 2015;(6).
42. Goldman RJ. Hyperbaric Oxygen Therapy for Wound Healing and Limb Salvage : A Systematic Review. PMRJ [Internet]. 2009;1(5):471–89. Available from: <http://dx.doi.org/10.1016/j.pmrj.2009.03.012>
43. Löndahl M, Fagher K, Katzman P. What is the Role of Hyperbaric Oxygen in the Management of Diabetic Foot Disease ? 2011;285–93.
44. Lack of Effectiveness of Hyperbaric Diabetic Foot Ulcer and the Prevention. 2013;